

Errors in Clinical Photography

Dr. Abhilasha.R¹, Dr. Ramesh.B², Dr. Chatura Hegde³, Dr. Hemanth.M⁴, Dr. Sharmada B.K⁵

Department Of Orthodontics And Dentofacial Orthopedics, Dayananda Sagar College Of Dental Sciences, RGUHS, Bangalore, India^{1,2,3,4,5}

Abstract: More than any other health specialty, dentistry has benefited from the trends and advances in digital photography, and a well-designed protocol of dental photography may be a great contribution for the orthodontic practice. Digital records may be used for several purposes, including patient records, treatment evaluation, patient counselling, medico-legal uses, as well as for marketing purposes. A good dental photography protocol may greatly enhance the dental practice. The aim of this article is to describe scientific and technical information in detail which will guide dentists who wish to use photography more efficiently..

Keywords: Clinical Photography, Digital Photography, Errors

I. Introduction

Clinical photographs taken before, during and after orthodontic treatment form an essential part of patient's records. If taken correctly, they offer useful information about the patients' malocclusion and treatment progress.¹ They are considered as essential diagnostic aids for a number of reasons. Firstly, they can be used to describe to patients, and parents about the various treatment biomechanics. Secondly, they are useful medicolegal requirements in our litigious society. Close-up photographs indicating any preexisting pathology or trauma will help avoid any post-treatment disputes. Thirdly, they serve as important teaching aids, to be used in lectures, papers, and presentations etc. Finally, they serve as reminders to patients and clinicians, of the original malocclusion and progress of the treatment thus.²

However, there are many potential sources of errors while obtaining these records. Photographs of inadequate quality may misrepresent the patients' initial malocclusion, may inaccurately reflect the progress or may incorrectly record dental anomalies and defects which may be present.

Thus, the aim of this paper, is to highlight the most common errors encountered while taking clinical photographs, the sources of these errors and methods to minimize these errors, to achieve the highest possible quality of photographic records.

Sources of Errors in Clinical Photography

There are a number of errors that are commonly seen and these can be divided into two groups. The first group comprises of technical errors due to inappropriate choice or use of equipment including the camera, lens, flash, retractors, mirrors or suction. The second group of errors relates to any recording medium and involves inappropriate positioning of the subjects.¹

1. Technical Errors

The correct equipment is required for high quality clinical photographs, which include a camera (either conventional or digital) with a macro-facility (ability to produce 1: 1 images) and, ideally, a ring flash, an appropriate background, suitable lighting and well trained assistants.

1.1 Camera- There are two types of digital cameras available; the "point & shoot" digital camera, and the DSLR (digital single lens reflex) cameras. The DSLRs are what professional photographers currently use, as they allow maximum flexibility and customization for the highest possible quality of digital images.

1.2 Flash- Ring flash vs Point flash- Point flash when used for clinical photographs, frequently produce distracting shadows, which may obstruct important details. These can be avoided by using a ring flash (Fig.1) which eliminates such shadows by allowing a more even and thorough distribution of light during extra and intra-oral photographs thus enhancing the quality of the image. (Fig. 2 and 3)



Fig.1- Ring Flash

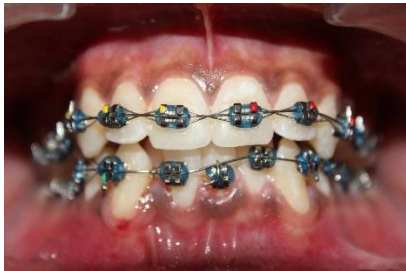

Fig.2

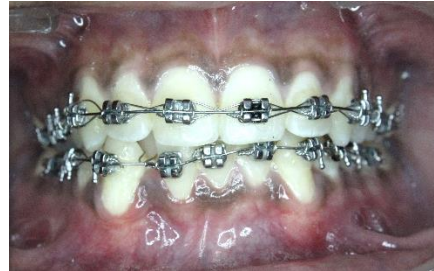

Fig.3

1.3 Macro-Lens- allows for taking close-up shots of objects in good focus and depth of field.

1.4 Cheek Retractors- two sets of double-ended retractors are used. One set with regular and small sized ends (small set), which are mainly used for intra-oral occlusal shots (mirror shots). The other set with narrow and a wide ends (large set) are used for intra-oral frontal and buccal shots. (Fig.4)



Fig.4- Set Of Cheek Retractors

1.5 Mirrors- many types of mirrors are used for clinical photography, ranging from front-silvered mirrors to highly-polished stainless steel mirrors. Front-silvered mirrors offer the best image quality and light distribution over other types of mirrors. In addition, it is preferred to use “long-handled” mirrors (Fig.5) as they allow better control and handling by the clinician during the occlusal shots.



Fig 5- Long Handled Intra Oral Mirrors

2. Positioning errors- Both the patient and the clinician need to be positioned correctly, in a standardized manner, to produce consistent photographs.

2.1 Extra-Oral Photographs

2.1.1 Full face and full face smiling views- the first photograph is taken with the lips at rest and the next one with the patient grinning broadly showing their teeth.

Commonly seen features of a poor extra-oral shot include –

1. The photograph taken in landscape orientation (Fig.6)
2. Wrong magnification (Fig.7) and
3. Too much of the patient’s torso in the photograph (Fig.8)
4. Formation of a shadow (Fig.9)



Fig.6



Fig.7



Fig.8



Fig.9

How to minimize these errors- an appropriate and consistent background should be selected, such as a non-reflective material, to eliminate shadows.

The following general guidelines should also be noted:

- A. The patient should stand with their head in the natural head position, with eyes looking straight into the camera lens. (Fig.10)
- B. The patient should hold their teeth and jaw in a relaxed (rest) position, with the lips in contact (if possible) and in a relaxed position. (Fig.11)
- C. Make sure patient's head is not tilted or their face rotated to either side; the shot should be taken at 90° to the facial mid-line from the front.
- D. Ensuring the patient's inter-pupillary line is levelled is very important. (Fig.11)



Fig.10



Fig.11

2.1.2 Profile and three-quarter profile views- usually only one profile (the patients right profile to match up with the lateral cephalogram and tracing) is taken. The back of the head is not necessarily required and it reduces the size of the frame occupied by areas of interest.

Errors with profile shots include-

- 1. Patient posturing with excessive tilting of the head forwards or backwards (Fig.12)
- 2. Subjects with long hair falling on the face. (Fig.13)
- 3. Area of interest is not fully exposed.(Fig.14)
- 4. Background noise.(Fig.15)
- 5. Distractions in the form of jewellery.(Fig.16)

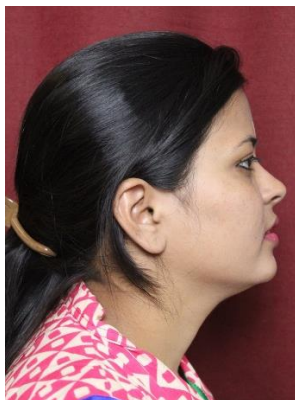


Fig.12



Fig.13



Fig.14



Fig.15



Fig.16

How to minimize these errors-

- A. The head should be in the natural head position, with their eyes fixed horizontally (preferably at a specific point at eye-level, or at the reflection of their own pupils in a mirror). (Fig.17 and 18)
- B. The whole of the right side of the face should be clearly visible with no obstructions such as hair, hats or scarfs.
- C. Taking extra-oral photos with the patient sitting on the dental chair or with multiple objects in the background should be avoided.
- D. The clinician should be standing a few feet away from the patient, and at the same eye level if possible. Younger and shorter patients should be made to stand on a special stand to get them to reach a suitable height, if needed.
- E. All extra-oral photos require that the aperture value (F value) be set to a minimum e.g. F8 is usually a suitable setting.

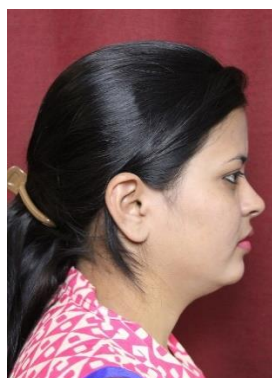


Fig.17



Fig.18

2.2 Intra-oral photographs

2.2.1 Anterior views- this is taken in 'landscape' view, with the teeth in occlusion filling the frame, with the occlusal plane horizontal and bisecting the picture.

Common errors include –

- 1. Canted occlusal planes (Fig.19)
- 2. Inappropriate selection and use of cheek retractors (Fig.20)
- 3. Saliva not aspirated (Fig.21)
- 4. The tongue not retracted before the photograph is taken
- 5. Bits of alginate left on the teeth

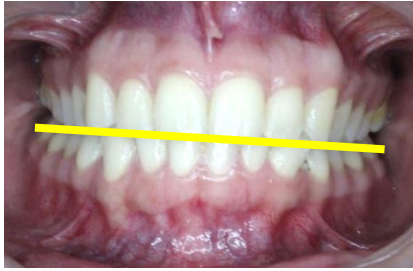

Fig.19

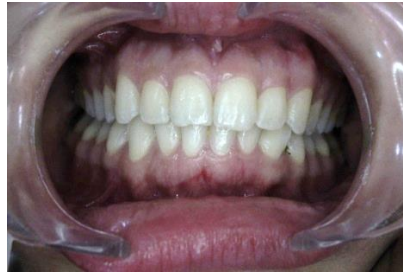

Fig.20

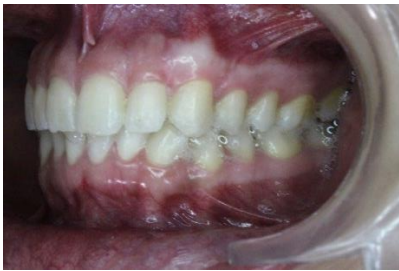

Fig.21

How to minimize these errors-

- A. The patient should be seated comfortably in the dental chair and raised to elbow-level of the clinician, the assistant should stand behind the patient and use the wide ends of the retractor to retract the patient's lips sideways and away from the gingivae. (Fig.22)
- B. The photo should be taken 90° to the facial mid-line using the upper frenal attachment as a guide and the full extension of the sulci visible. (Fig.23)
- C. The high F value setting e.g. F32 is required to attain maximum depth of field of the shot with even the last visible molars fully in focus.
- D. The ring-flash should be used to ensure the best possible light distribution of the image without shadows.

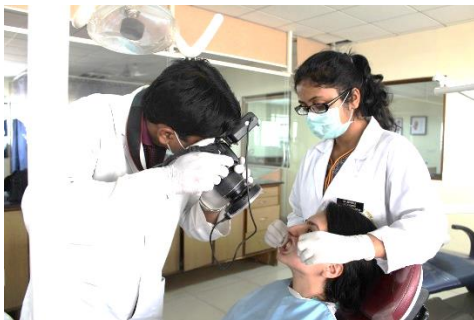

Fig.22

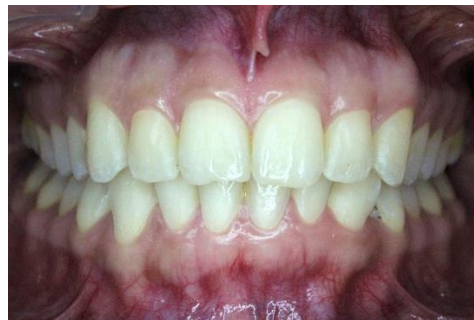

Fig.23

2.2.2 Buccal views

Again the occlusal plane should be horizontal and bisect the frame. The frame should be filled with teeth extending from the mesial surface of the central incisor to at least the distal surface of the first permanent molars and further posteriorly if possible. It is important to angle the camera so that the lens is perpendicular to a tangent to the buccal surfaces of the posterior teeth to avoid underestimation of the sagittal discrepancy.

How to minimize errors- the patient is asked to turn their head slightly to their left so their right side will be facing the clinician. Here, the clinician holds the right retractor and stretches it to the extent that the last present molar is visible if possible, while the assistant maintains hold of the left retractor, without undue stretching. (Fig.24)

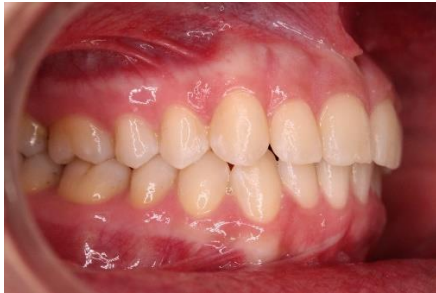

Fig.24

2.2.3 Mirror Views

The upper and lower mirror shots should ideally be symmetrical views of the occlusal surfaces of the teeth, extending from just in front of the incisors to at least the distal surfaces of the first molars and ideally to include all the erupted teeth. There should be no direct view of the incisor teeth and the area covered should be clearly visible without any fogging. (Fig.25)

How to Minimize Errors- Upper Occlusal-

- A. With the patient's mouth held open, the retractors should be inserted in a "v" shape to retract the upper lips *sideways and away* from the teeth.
- B. The clinician should insert the mirror with its wider end inwards to capture maximum width of the arch posteriorly, and pull it slightly downwards so that the whole upper arch is visible to the last present molar.
- C. The patient should be instructed to lower their head slightly so that the shot can be taken 90° to the plane of the mirror for best visibility.
- D. The mid-palatal raphe is used as a guide for the orientation of the shot to get it levelled.(Fig.26)

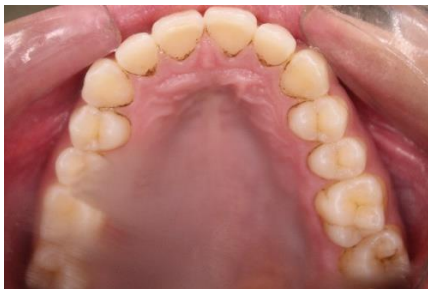

Fig.25

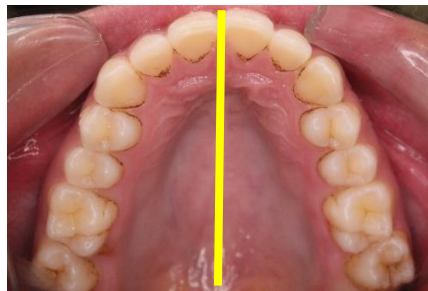


Fig.26

Lower Occlusal

- A. The assistant should lower the smaller retractors into a reverse “v” shape to retract the lower lips sideways and away from the teeth.
- B. The clinician should lift the mirror upwards so that he can visualize the reflection of the lower arch, while the patient is asked to “lift their chin up” slightly.
- C. The patient is asked to “roll back” their tongue behind the mirror so that it won’t interfere with the visibility of any teeth, particularly in the posterior area.(Fig.27)
- D. The shot should be taken 90° to the plane of the mirror, with the last molar present visible.(Fig.28)

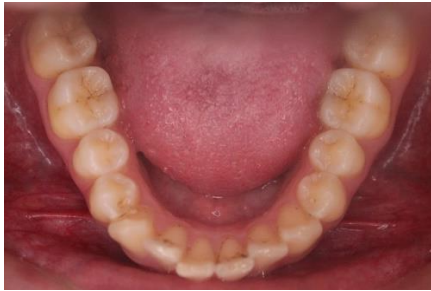

Fig. 27

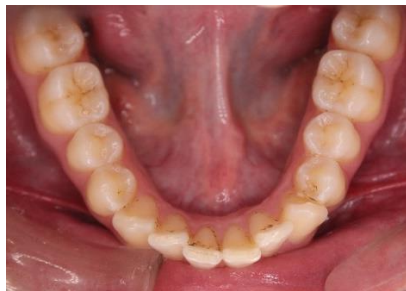

Fig.28

Points to be noted

- 1. The direction of pull of the retractors is always sideways and slightly forward, away from the gingival tissues. This maximizes the field of view and minimizes patient discomfort.
- 2. Wetting the retractors just before insertion eases the process of positioning them properly with minimum patient discomfort.
- 3. When taking occlusal “mirror” shots, slightly warming the mirror prior to insertion helps prevent “fogging” of the mirrors.
- 4. A saliva ejector can be used to eliminate saliva prior to taking each photograph.
- 5. It is recommended to take photographic records before recording impressions, to eliminate the possibility of impression material being stuck between the teeth or on the face.

II. Conclusion

Good quality accurate clinical photographs can easily be obtained using the correct equipment and appropriately trained staff. An awareness of all the possible errors in extra- and intra-oral clinical photography will increase the chances of obtaining high quality images.

References

- [1] Mckeown HF, Murray Am, Sandler Pj. How to avoid common errors in clinical photography. Journal Of Orthodontics, Vol. 32, 2005, 43–54
- [2] Sandler PJ, Murray Am. Clinical photography in orthodontics. J Clin Orthodont 1997; 31: 729–39.